

Localized Hypertrichosis following BCG Vaccination

P Öztas*, F Çatal**, U Dilmen†

Summary

Öztas P, Çatal F, Dilmen U. Localized Hypertrichosis following BCG Vaccination *Nigerian Journal of Paediatrics* 2003;30:93. An eight-month-old Turkish boy presented at the Fatih University Pursaklar outpatient clinic with excessive hair on his left shoulder. The history was that 15 days after receiving BCG vaccination at the age of two months, new hairs were noticed at the site. Examination revealed an aggregation of dark hairs on an area measuring 4x3cm at the site of the vaccination with the scar of BCG vaccine at the base. We would like to draw attention to this hitherto unreported localized hypertrichosis complicating BCG vaccination.

Keywords: BCG vaccine, hypertrichosis, side effect

Introduction

BCG vaccine, the only proven effective vaccine for the prevention of tuberculosis, is routinely administered in developing countries and since 1955, in Turkey. There are many well-known side effects reported in the literature.¹ However, as far as we are aware, the development of hypertrichosis at the injection site has not been reported before. In this communication, we present such a case.

Case Report

An eight-month-old Turkish boy presented at the Fatih University Pursaklar outpatient clinic with a history of having an excessive amount of hair on his left shoulder. He was born at term in a government hospital in Ankara, Turkey, with a birth weight of 2900g, following a normal pregnancy. The first child of healthy unrelated parents, he had no perinatal problems. He

Ankara Numune Education Hospital, Ankara, Turkey

Dermatology Clinic

* Consultant Specialist

Fatih University Faculty of Medicine, Ankara

Department of Pediatrics

** Consultant Specialist

†Professor

Correspondence: Pinar ÖZTAS, E-mail: poztas@yahoo.com

had received BCG vaccine on his left shoulder at the age of two months. Fifteen days after the vaccination, tiny hairs started to appear in the area where the vaccine was injected. There had been no local trauma, no history of chronic dermatological disease neither was he receiving any drug. Furthermore, the parents had not applied any medicine or herbal medications to the BCG site.

Physical examination revealed a well-developed child with a weight of 8.3 kg (25th-50th percentile), height 71 cm (50th percentile), and head circumference 45.3 cm (50th percentile). There were no abnormal findings apart from an aggregation of dark hairs on an apparently normal skin in an area measuring 4x3 cm on the left shoulder, with a BCG scar at the base of the hypertrichotic area (Fig 1); the right shoulder was normal.

During a three-month follow-up period, there was no change in the lesion, which still persisted 10 months after presentation (Fig 2); while the other shoulder remained normal (Fig 3).

Discussion

After decades of decline in the incidence of tuberculosis (TB),¹ the number of TB cases has increased dramatically over the past decade due largely to a combination of factors namely, immigration of affected individuals from high prevalence areas, immunosuppression caused by epidemics of human

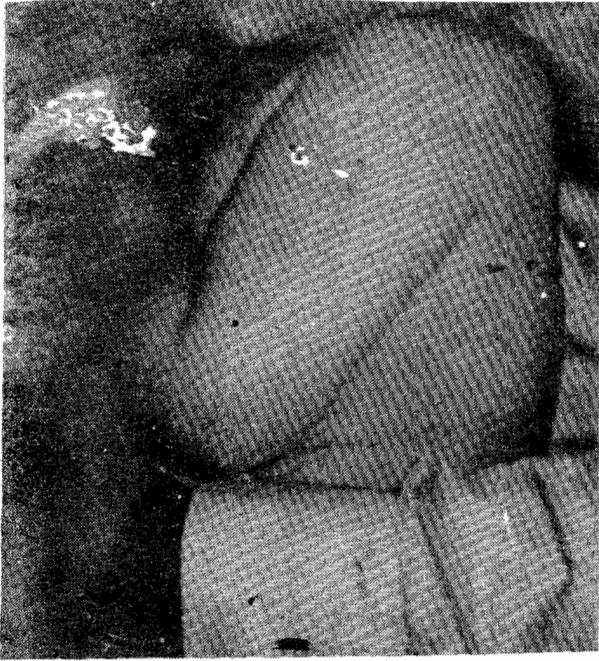

Figure 1. Localized hypertrichosis on the left shoulder of the patient, six months following BCG immunization.

immunodeficiency virus (HIV) infection and limitations in health care services to high-risk populations. The only vaccine available against tuberculosis is still the Bacille Calmette-Guérin (BCG).¹ The efficacy rate of the vaccine in protecting against TB ranges from 0 to 80 percent. A meta-analysis of data from 14 prospective trials and 12 case-control studies of BCG efficacy showed that the vaccine reduces the risk of tuberculosis by an average of 50 percent,² the prevention rate reported in Turkey is about 80 percent.³ This vaccine does not contain any additive or preservative and the preferred route of administration is intradermal injection.

The most common side effects of BCG immunization are abscess formation, local ulceration and regional suppurative adenitis; these occur in 0.1-1.0 percent of vaccine recipients.^{1,4} Osteitis is a rare complication, while constitutional symptoms such as fever, convulsions, loss of appetite and irritability are extremely rare.¹ Hypertrichosis is a generalized or a localized increase in the non-sexual, non-androgen dependent hair of the body.⁵ Localized hypertrichosis may be associated with local trauma, malnutrition, long-standing inflammatory dermatoses, and drugs like steroids, minoxidil, danazol, diazoxide, and phenytoin. Contact eczema, thrombophlebitis, pretibial myxoedema, arthritis, occupational or self-induced trauma have also been associated with this

phenomenon.⁵ The possible cause of localized hypertrichosis in our patient seems to be the inflammation induced by the BCG vaccine. Harper *et al*, reported localized acquired hypertrichosis in association with fractures of the arm in young girls,⁶ while Becker nevus following BCG vaccination has been reported.⁷ To our knowledge however, our patient is the first case with localized hypertrichosis triggered by BCG vaccination.

The exact mechanism of how and why BCG immunization causes hypertrichosis is unknown. However, it is known that BCG vaccination generally induces strong lymphoproliferative effect and T-helper type 1-type cytokine responses, especially involving IL-5 and IL-10. Cytotoxic activity correlates with the ratio of IFN-gamma to IL-5.⁸ Considering the pathogenesis of how hairs arise after contact eczema or chronic trauma, it would appear that some immunological factors play a major role. In the treatment modalities of alopecia areata, topical sensitizers such as SADBE (squaric acid dibutyl ester) or DPCP (diphenylcyclopropenone) are being widely used. These drugs show their main therapeutic effect by immunoalteration, with a change in CD4/CD8 lymphocyte ratio.⁹ While dermal inflammation may be followed by hair growth at the injection site,⁵ such inflammation is usually due to vaccine additives such as thiomersal.¹⁰ However, BCG vaccine contains no additive such as thiomersal or aluminium; therefore, the inflammation seems to be primarily due to the immunological effect of the BCG vaccine itself.

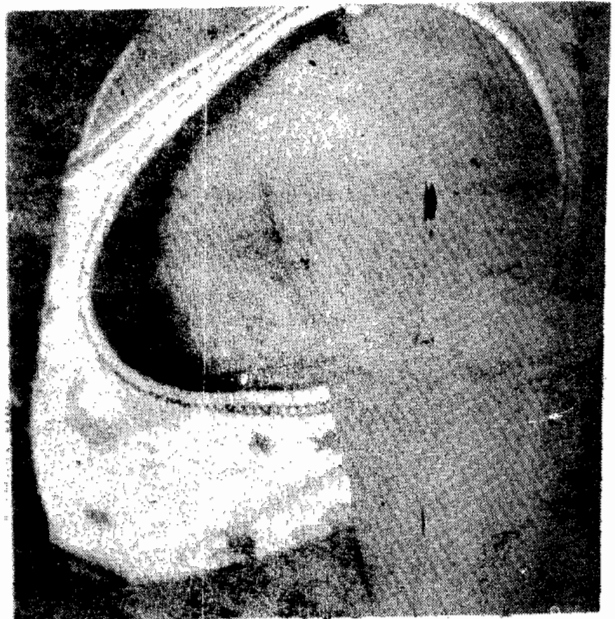


Figure 2. Localized hypertrichosis on the left shoulder of the patient, 16 months following BCG immunization.

References

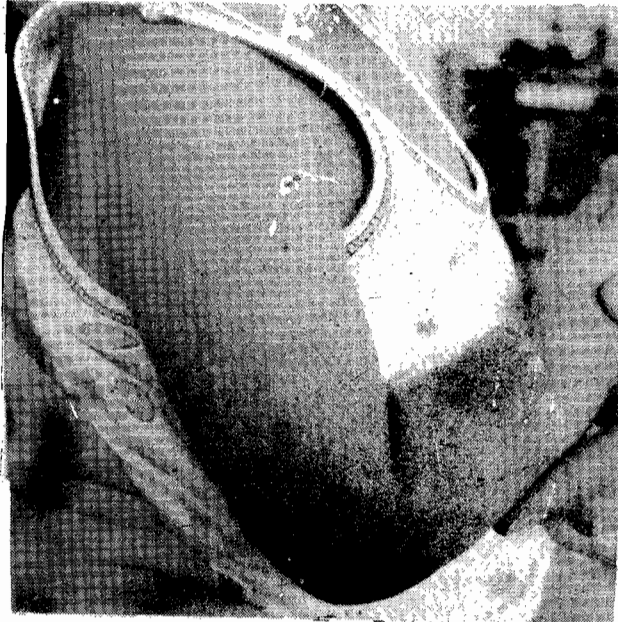


Figure 3. The right shoulder of the patient showing an absence of hairs.

Although we believe that such side effects may be caused by the direct immunologic effect of living organism in the vaccine, it is still unclear why hypertrichosis is an apparently rare condition. Investigation of the affected tissue using immunopathological methods are essential in order to further elucidate the pathophysiology of the process. Unfortunately, we could not perform such a histopathological examination in our patient since the reaction had occurred six months before the patient first presented. Meanwhile, we wish to draw attention to this rare adverse effect of BCG; we suspect that more cases may be reported in future if BCG injection sites are carefully examined after routine immunizations.

1. Jeffrey RS. Tuberculosis. In: Nelson Textbook of Pediatrics. Behrman RE, Kliegman RM, Arvin AM, eds. Philadelphia: WB Saunders Company, 1996:834-47.
2. Brewer TF. Preventing tuberculosis with bacillus Calmette-Guerin vaccine: a meta-analysis of the literature. *Clin Infect Dis* 2000; **31**: 64-7.
3. TC Sağlık Bakanligi Verem Savas Daire Baskanligi, Tüberküloz Hastalarinin Tani-Tedavi ve Izlenmesi. p 16 (local reference).
4. Turrbull FM, McIntyre PB, Achat HM, Wang H, Stapledon R, Gold M, Burgess MA. National study of adverse reactions after vaccination with bacille Calmette-Guerin. *Clin Infect Dis* 2002; **34**: 447-53.
5. Özkan H, Dundar NO, Ozkan S, Kumral A, Duman N, Gulcan H. Hypertrichosis following measles immunization. *Pediatric Dermatol* 2001; **18**: 457-8.
6. Harper MC. Localized acquired hypertrichosis associated with fractures of the arm in young females. A report of two cases. *Orthopedics* 1986; **9**: 73-4.
7. Svindland HB, Wetteland P. A case of pigmentary hair naevus (Becker). *Acta Derm Venereol* 1975; **55**:141-5.
8. Hussey GD, Watkins ML, Goddard EA, Gottschalk S, Hughes EJ, Iloni K, Kibel MA, Riss SR. Neonatal mycobacterial specific cytotoxic T-lymphocyte and cytokine profiles in response to distinct BCG vaccination strategies. *Immunology* 2002; **105**: 314-24.
9. Rokhsar CK, Shupack JL, Vafai JJ, Washenik K. Efficacy of topical sensitizers in the treatment of alopecia areata. *J Am Acad Dermatol* 1998; **39**: 751-61.
10. Stavrianeas NG, Katoulis AC, Kanelleas A, Hatzilou E, Georgala S. Papulonodular/lichenoid and pseudolymphomatous reaction at the injection site of hepatitis B virus vaccination. *Dermatology* 2002; **205**: 166-8.